

# **Infiltrative Oncocytoma arising from minor salivary glands of palate: A Case Report**

1. **Sonika** (MDS), Dental Surgeon, Tamilnadu, India.
  2. **A Sri Kennath J Arul\*** Pathology, Best Dental Science College Madurai, Tamilnadu, India.
  3. **A Sri Sennath J Arul** (MD) Medical Practitioner, Tamilnadu, India
  4. **S.Chitra** (BDS) Dental surgeon, Tamilnadu, India.
  5. **S. Prabhu** (MDS) Oral and Maxillofacial Surgeon, Tamilnadu, India
- 

## **ABSTRACT**

Oncocytoma of salivary gland origin is an uncommon tumor found exclusively in the parotid gland. On rare occasions, oncocytoma arise in the intra-oral minor salivary glands; having a greater tendency for locally aggressive behavior and infiltrating the adjacent tissues due to incomplete capsulation. The current case is of particular interest due to the infiltrating nature of the lesion in a 70-year-old male patient, who denied any leading symptoms, even with the lesion involving extensively. Lack of distinguishing clinical symptoms and histopathological similarity to a number of entities pose diagnostic difficulty. Sound knowledge of the clinicopathologic features and biological behavior of intra-oral oncocytic tumors is important to ascertain precise diagnosis; and establishing appropriate treatment aimed at a good clinical course.

**Key words:** Aggressive, infiltrative, maxillary antrum, oncocytoma, palate

---

## **1. INTRODUCTION**

Oncocytoma is a rare benign tumor that accounts for about 1% of all salivary gland neoplasms.<sup>1</sup> It is predominantly a tumor of the major salivary glands with the vast majority seen in the parotid gland of older adults.<sup>2</sup> Only a small percentage are found in the minor salivary glands of the palate, buccal mucosa, lower lip; nasal cavity, including the maxillary antrum; tonsillar fossa; larynx and the lacrimal gland.<sup>1,3</sup>

The clinicopathologic features of minor salivary or seromucous gland oncocytic tumors are sufficiently distinctive from those in major salivary glands as to warrant separate discussion. Oncocytomas arising from minor salivary glands are not encapsulated and tend to infiltrate the adjacent soft and bone tissues. They behave more aggressively than the typical oncocytomas and hence are classified under the group 'locally aggressive oncocytomas'.<sup>4,5</sup>

Microscopically, the tumor is composed exclusively of large epithelial cells with characteristic bright eosinophilic granular cytoplasm i.e. oncocytes. Focal clear cell change may be seen, with rare tumors being composed almost entirely of clear cells, called clear cell oncocytomas.<sup>6</sup> The presence of oncocytic metaplasia in other salivary gland tumors, clear cell tumors and salivary gland tumors comprising of large cells with granular cytoplasm; pose diagnostic confusion making histopathological differential interpretation of oncocytoma challenging. However careful histologic sampling aids in revealing other characteristic components of salivary gland tumors and thus allows proper tumor classification.



In view of its rarity, the present case of oncocytoma arising from minor salivary glands of palate in a 70-year-old male, infiltrating the maxillary antrum and adjacent tissues is herewith reported.

## **2. CASE REPORT**

A 70-year-old male patient was referred to our service for the evaluation of a progressively enlarging swelling on the hard palate since 1 year. Extra-oral examination revealed no significant findings. On intra-oral examination, an extensive swelling with well-defined limits was observed involving the palatal mucosa. The swelling extended anteriorly from the left maxillary second premolar to the junction of hard and soft palate posteriorly; approximating the mid-palatal region. The mucosa overlying the most dependent part of the swelling was erythematous with blanched appearance at the periphery (Figure 1a). On palpation, the swelling was soft to firm in consistency; non-tender. No palpable cervical lymphadenopathy was present. Medical history was non-contributory to the present complaint. Patient denied any treatment during the first visit.

Within a period of one month, there was considerable increase in the size of intra-oral swelling with associated difficulty in mastication and swallowing. The soft tissue mass extended to involve the entire left palatal mucosa and crossed the midline. The mucosa overlying the central part of the swelling was erythematous with necrotic centre (Figure 1b).

Water's view showed haziness in both left and right maxillary antrum without any evidence of erosion of lateral walls of the antrum. Further to delineate the extent of the lesion, a computed tomography (CT) scan was carried out. CT scan (axial and coronal views) demonstrated a hypodense ill-defined expansile lesion of the left maxilla and involvement of the left maxillary antrum. Destruction of the bony margins of medial and lateral walls of the left maxillary antrum, with extension into the nasal cavity was evident. CT scan also revealed destruction of the bony margin of the right maxillary antrum (Figure 2a and b). In view of these findings, a diagnostic possibility of minor salivary gland tumor of palate was hypothesized with differential diagnosis of pathology arising from the maxillary antrum.

Subsequently, an incisional biopsy was performed and the specimen was submitted for the histopathological examination. Light microscopic examination of the sections stained with H-E revealed the tumor cells present as solid sheets having distinct cellular boundaries. The tumor cells (oncocytes) appeared as large, epithelial cells with brightly eosinophilic cytoplasm having prominent granularity; exhibited large vesiculated nucleus with prominent nucleoli. Sheets of oncocytes were supported by thin fibrovascular stroma (Figure 3). Local infiltration of fibrous capsule, focal cellular pleomorphism and scattered mitotic figures were not appreciated. The histopathological features were suggestive of benign oncocytoma. The tumor was surgically excised under general anesthesia and the postoperative course was uneventful. Treatment planning for dental rehabilitation is currently underway and the patient has been kept on regular follow-up.

## **3. DISCUSSION**

The term oncocytoma was first used by Jaffe, although differently from its present connotation, to describe what is currently considered to be Warthin's tumor.<sup>7</sup> In 1931, Hamperl first applied the term oncocyte to cells that make up what is now considered to be oncocytoma.<sup>8</sup> Other descriptive terms used for the tumor



are oxyphilic adenoma, oxyphilic granular cell adenoma, oncocytic adenoma and acidophilic granular cell tumor.<sup>9-12</sup>

Oncocytic lesions are rare in the oral cavity; the palate and buccal mucosa are the most common sites.<sup>2</sup> Lesions infiltrating the nasal cavity are rare causing nasal obstruction, epistaxis and rhinorrhoea;<sup>13</sup> the findings that were not appreciated in the present case; albeit the lesion extended to involve the nasal cavity as evident on the CT scan.

Intra-oral oncocytomas fail to demonstrate any distinguishing clinical symptoms that would permit differentiation from other benign and malignant minor salivary gland tumors. Unlike major salivary gland oncocytomas, those in the sinonasal tract have a male preponderance and are generally larger than benign tumors. Although histologically benign, they are clinically more aggressive, with a propensity to affect the maxilla or nasal cavity,<sup>14</sup> as observed in the present case. No definitive etiologic factors for this tumor have been suggested, although there has been an association with radiation in some reports;<sup>15</sup> but no history of radiation therapy or exposure was documented in the present case.

Furthermore, the hyperplastic versus neoplastic basis for many of the oncocytic lesions has not been settled. Many studies have suggested oncocytes represent a degenerative process, as these cells can be observed in otherwise normal specimens from aged patients. However, the large size and growth pattern of some oncocytomas; malignant transformation of previously benign oncocytic lesions; as well as the existence of de-novo oncocytic adenocarcinoma would seem to endorse the existence of a neoplastic process.<sup>2</sup>

The intra-oral oncocytic lesions may span the spectrum from oncocytic papillary cystic tumors with a variable degree of lymphocytic infiltrate to more solid oncocytomas. The microscopic differential diagnosis include salivary gland tumors exhibiting oncocytic metaplasia (mainly mucoepidermoid carcinoma and pleomorphic adenoma; and rarely epithelial-myoeithelial carcinoma, myoeithelioma, basal cell adenoma and acinic cell carcinoma); clear cell tumors (acinic cell carcinoma, clear cell carcinoma not-otherwise-specified, mucoepidermoid carcinoma, epithelial-myoeithelial carcinoma, and metastatic renal cell carcinoma); and other salivary tumors consisting of large cells with granular cytoplasm that includes salivary duct carcinoma and granular cell tumor. In the sinonasal tract, the differential diagnosis includes oncocytic cylindrical cell papilloma, moderately differentiated neuro-endocrine carcinoma, and low-grade intestinal-type adenocarcinoma.<sup>6</sup> Careful histologic sampling reveals other characteristic components of these tumors; thus allows for appropriate diagnosis. Furthermore, PTAH staining and electron microscopy can be useful to identify the increased cytoplasmic mitochondrial content of oncocytes.<sup>15</sup>

Oncocytomas of the minor salivary gland origin should be completely excised, together with a small margin of uninvolved soft tissue, since these lesions occasionally have a thin incomplete capsule. Since rare malignant cases of oncocytic carcinoma have been reported,<sup>3</sup> therefore long-term follow up is recommended.

#### **4. CONCLUSION**

Minor salivary gland origin oncocytomas are rare. Knowledge about their biologic behavior that differs from the major salivary gland counterparts is therefore, imperative so that appropriate treatment can be instituted to the pathological entity.



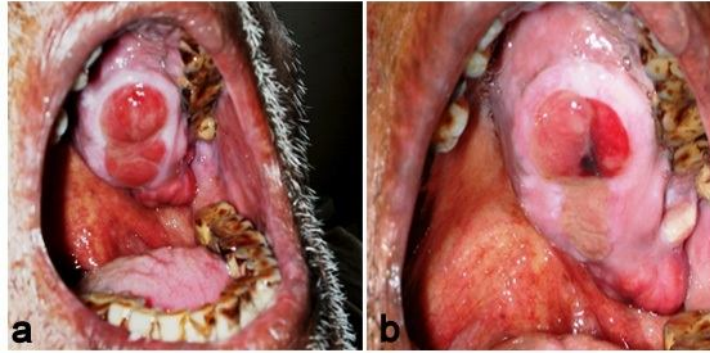


Figure.1a

Figure.1b

**Figure 1a:** Intra-oral swelling involving the left palatal mucosa

**Figure 1b:** Enlargement of intra-oral mass involving entire left palatal mucosa and crossing midline of palate

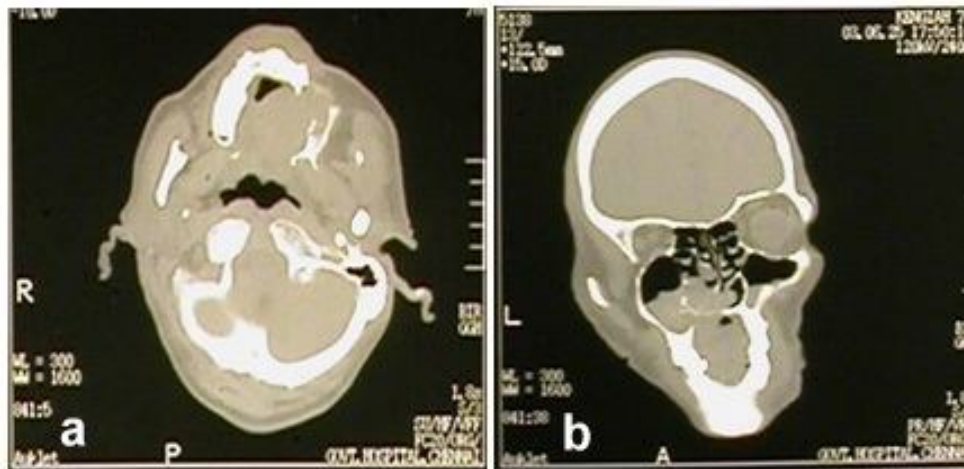

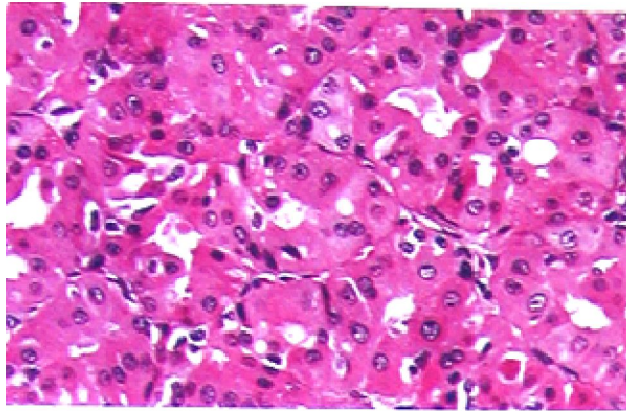
Figure.2a

Figure.2b

**Figure 2a:** Axial CT view depicting an expansile lesion of the left maxilla

**Figure 2b:** Coronal CT view showing involvement of the left maxillary antrum and extension of the lesion into the nasal cavity. Involvement of right maxillary antrum is also evident.





**Figure 3:** Photomicrograph of the histopathologic section reveals sheet of oncocytes exhibiting brightly eosinophilic cytoplasm having prominent granularity; large vesiculated nucleus with prominent nucleoli (H-E Stain)

## 5. REFERENCES

1. Barnes L, Eveson JW, Reichart P, Sidransky D. World Health Organization Classification of Tumors. Pathology and Genetics of Head and Neck Tumors. Lyon: IARC Press, 2005. p. 266.
2. Ellis GL, Auclair PL, Gnepp DR. Surgical Pathology of the Salivary Glands. Philadelphia: W.B. Saunders, 1991. p. 225-37.
3. Kanazawa H, Furuya T, Murano A, Yamaki M. Oncocytoma of an intraoral minor salivary gland: Report of a case and review of literature. *J Oral Maxillofac Surg.* 2000; 58: 894-7.
4. Cohen MA, Batsakis JG. Oncocytic tumors (oncocytomas) of minor salivary glands. *Arch Otolaryngol.* 1968; 88: 71-3.
5. Gray SR, Cornog JL Jr, Seo IS. Oncocytic neoplasms of salivary glands: A report of fifteen cases including two malignant oncocytomas. *Cancer* 1976; 38: 1306-17.
6. Gnepp DR. Diagnostic Surgical Pathology of the Head and Neck, 2nd ed. Philadelphia: W.B. Saunders, 2009. p. 465.
7. Jaffe RH. Adenolymphoma (oncocytoma) of the parotid gland. *Am J Cancer* 1932; 16: 1414-23.
8. Hamperl H. Onkocyten und Geschwulste der Speicheldrüsen. *Virchows Arch J Path Anat.* 1931; 282: 724-36.
9. Foote FW Jr, Frazell EL. Atlas of Tumor Pathology: Tumors of the Major Salivary Glands. Washington, DC: Armed Forces Institute of Pathology; 1954. p. 137.
10. Meza-Chavez L. Oxyphilic granular cell adenoma of the parotid gland (oncocytoma): Report of five cases and study of oxyphilic granular cells (oncocytes) in normal parotid glands. *Am J Pathol.* 1949; 25: 523-47.
11. Stump DJ. Onkocytic adenoma of the salivary glands. *Arch Pathol (Chic).* 1949; 48: 287-96.



12. Buxton RW, Maxwell JH, French AJ. Surgical treatment of epithelial tumors of the parotid gland. *Surg Gynecol Obstet.* 1953; 97: 401-16.
13. Comin CE, Dini M, Lo Russo G. Oncocytoma of the nasal cavity: report of a case and review of the literature. *J Laryngol Otol.* 1997; 111: 671-3.
14. Fayet B, Bernard JA, Zachar D, D'Hermies F, Janot F, Pigeau I; et al. Malignant nasal oncocytoma disclosed by mucocele of the lacrimal sac with hemolacrimia. *J Fr Ophtalmol.* 1990; 13: 153-8.
15. Zhou CX, Gao Y. Oncocytoma of the salivary glands: A clinicopathologic and immunohistochemical study. *Oral Oncol.* 2009; 45:e 232-8.

